CASE REPORT

Noninvasive Administration of Inhaled Epoprostenol and Inhaled Milrinone in Extubated, Spontaneously Breathing Patients With Right Ventricular Failure and Portal Hypertension: A Report of 2 Cases

Etienne J. Couture, MD,*† Jan-Alexis Tremblay, MD,*† Mahsa Elmi-Sarabi, MSc,*‡§
Yoan Lamarche, MD, MSc,*§‖ and André Y. Denault, MD, PhD*‡§¶

We describe the cases of 2 patients free from mechanical ventilation after a cardiac surgery with systemic venous congestion from right ventricular (RV) failure. Management of these patients included RV preload reduction with diuretics and RV afterload reduction with inhaled pulmonary vasodilators. Noninvasive combination of inhaled epoprostenol and inhaled milrinone through the AirLife filtered nebulizer system (CareFusion) was used. Reduction of splanchnic venous congestion was assessed by Doppler portal flow pulsatility. (A&A Practice. 2019;12:208–11.)

Downloaded from http://journals.lww.com/aacr by BhDMf5ePHKbH4TTImqenVlUKVF7qTxstCK8yuWvzyZZ4W6x7Ac22dnfNwL2E4eoOLTYhOXaM= on 02/14/2020

The combination of inhaled epoprostenol and inhaled milrinone is associated with improved cardiac function in the operating room[1] and the intensive care unit (ICU).[2] We report the use of a noninvasive device to deliver inhaled epoprostenol and milrinone in 2 extubated patients presenting extracardiac signs of right ventricular (RV) dysfunction.[3,4] Both patients provided written consent for publication.

CASE DESCRIPTIONS

Patient 1

A 71-year-old man known for a severe coronary artery disease was transferred from a community hospital with unstable angina. Transthoracic echocardiography revealed a severe aortic stenosis, a left ventricular (LV) ejection fraction of 60%, a systolic pulmonary arterial pressure (SPAP) of 70 mm Hg, and a severe tricuspid regurgitation. He underwent coronary revascularization, aortic valve replacement, and a tricuspid valve annuloplasty. Cardiopulmonary bypass (CPB) weaning was done using norepinephrine (0.09 μg/kg/min) and was marked by RV failure that necessitated a return on CPB and 5 mg of intratracheal milrinone.[5] Second weaning attempt was successful. Total CPB time was 142 minutes with an intraoperative net fluid balance of 1192 mL. At the end of the procedure, the mean arterial pressure (MAP) was 72 mm Hg, the MAP over the mean pulmonary artery pressure (MPAP) or MAP/MPAP ratio was 1.95, cardiac output was 3.79 L/min, systemic vascular resistance was 1098 dynes·s·cm^{-5}, and central venous pressure (CVP) was 20 mm Hg. Transesophageal echocardiography showed no significant aortic gradient nor perivalvular leak, and a complete resolution of the tricuspid regurgitation. Doppler signals on all grafts were normal. At the arrival at the surgical ICU, the patient had a cardiac output of 2.84 L/min, a CVP of 16 mm Hg, and MAP/MPAP ratio of 2. During the first 6 hours in the ICU, the patient received 2 doses of 75 μg of inhaled epoprostenol.[1] After treatment, the MAP/MPAP ratio increased to 2.5, CVP decreased to 12 mm Hg, norepinephrine was weaned, and the patient was extubated 7 hours after ICU admission by use of a standard protocol based on adequate neurological status, gas exchange, and minimal hemodynamic support. During the first night, the patient developed acute renal failure and peripheral edema. Pulmonary hypertension with a SPAP of 57 mm Hg, MAP/MPAP ratio of 1.76, CVP of 24 mm Hg, and failure to respond to diuretics led to the introduction of intravenous milrinone at 0.25 μg/kg/min. His condition was associated with 38% portal vein pulsatility. Six hours after milrinone infusion, diuresis increased and it was decided to add inhaled nitric oxide at 20 parts per million using nasal cannula in an attempt to reduce RV afterload. On postoperative day 2, milrinone was weaned and a noninvasive combination of 60 μg of inhaled epoprostenol plus 4 mg of inhaled milrinone was given every 4 hours using the AirLife filtered nebulizer system (CareFusion, Vernon Hills, IL; Figure 1). After the introduction of inhaled agents, a marked increase in urinary output and a decrease in serum creatinine level were observed in association with a significant decrease in SPAP, MPAP, CVP, and portal flow pulsatility (Figure 2). This therapy was continued for 32 hours and led to resolution of the acute renal failure with return to preoperative creatinine level at postoperative day 7 without any further diuretics or vasoactive support.

Patient 2

An African American woman of 20 years of age was referred for hemodynamic evaluation and pericardectomy. She presented a 6-month history of dyspnea, fatigue, weight loss,

From the *Research Centre, ‡Department of Anesthesiology, ‖Department of Cardiac Surgery, §Division of Critical Care, Montreal Heart Institute, †Division of Critical Care, Department of Medicine, Université de Montréal, Montreal, Quebec, Canada; and ¶Division of Critical Care, Centre Hospitalier de l'Université de Montréal, Montreal, Quebec, Canada.

Accepted for publication July 1, 2018.

Funding: Richard I. Kaufman Endowment Fund in Anesthesiology and Critical Care.

Conflicts of Interest: See Disclosures at the end of the article.

All authors gave final approval of the version to be published. All authors agree to be accountable for all aspects of the work in ensuring that questions related to the accuracy or integrity of any part of the work are appropriately investigated and resolved.

Address correspondence to André Y. Denault, MD, PhD, Department of Anesthesiology, Montreal Heart Institute, 5000 Belanger St, Montreal, QC H1T 1C8, Canada. Address e-mail to andre.denault@gmail.com.

Copyright © 2018 International Anesthesia Research Society
DOI: 10.1213/XAA.0000000000000886

Copyright © 2018 International Anesthesia Research Society. Unauthorized reproduction of this article is prohibited.

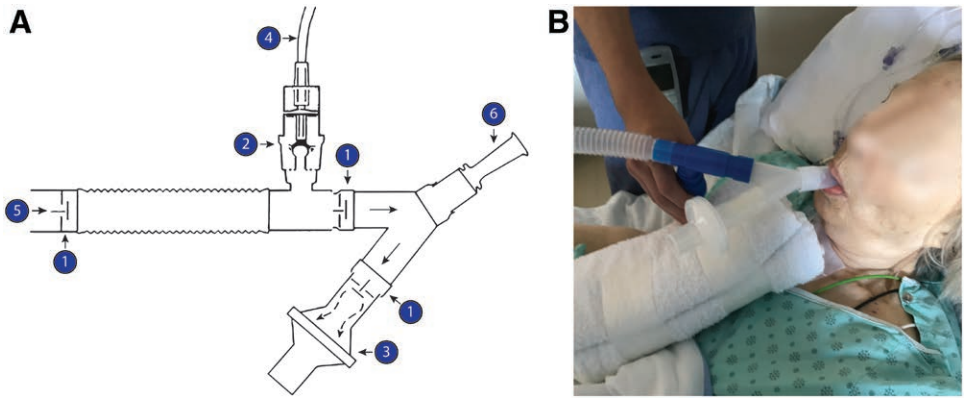

Figure 1. Noninvasive inhalation device. A, AirLife filtered nebulizer system (CareFusion, Vernon Hills, IL). Adapted from Miller et al.[6] B, Use of the system on a patient in the intensive care unit. 1, One-way valve; 2, nebulizer; 3, expiratory filter; 4, power gas tubing; 5, intake; and 6, mouthpiece.

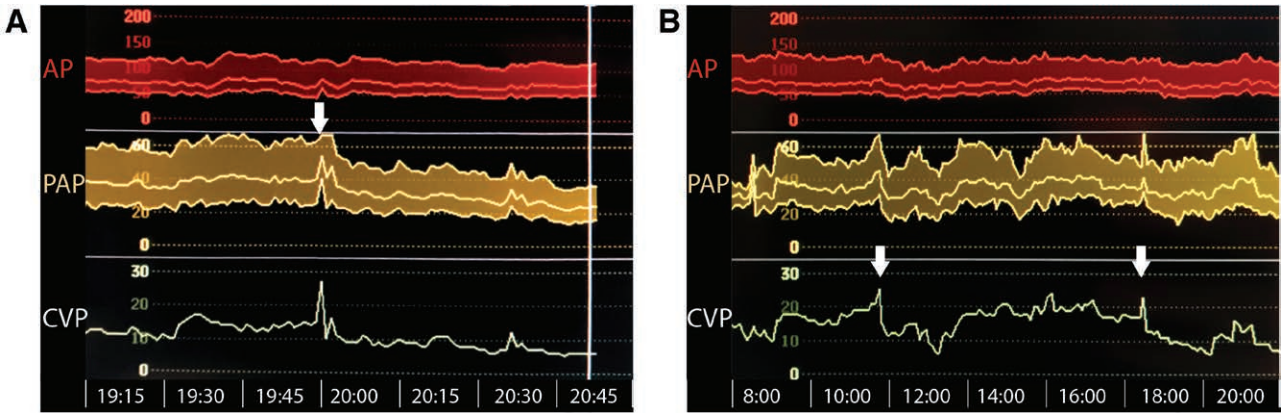

Figure 2. Hemodynamic effect of noninvasive inhaled therapy. Patient 1 (A) systemic AP, PAP, and CVP after inhalation of both epoprostenol and milrinone (arrows). Note the reduction of the PAP without any change in the AP. B, Repeated effect of inhaled agents (arrows) on the PAP and the CVP. Note that on both occasions during inhalation (arrows), a significant reduction of CVP was observed. AP indicates arterial pressure; CVP, central venous pressure; PAP, pulmonary artery pressure.

and leg swelling. Thoracic scan revealed an 11-mm diffuse pericardial thickening with multiple mediastinal lymphadenopathies from latent tuberculosis. Preoperative transthoracic echocardiography revealed absence of valvular disease, SPAP of 40 mm Hg, LV ejection fraction of 60%, normal RV size and function, and echocardiographic signs of constrictive pericarditis. The patient underwent an extensive pericardectomy and maintained an MAP of 70 mm Hg with a perfusion of phenylephrine ranging from 0 to 0.8 μg/kg/min. Intraoperative transesophageal echocardiography revealed normal RV systolic and diastolic function. She was extubated 4 hours after admission in the ICU using the same protocol as for patient 1. Postoperative day 1 was uneventful. During postoperative day 2, she progressively developed hemodynamic instability requiring norepinephrine up to 0.25 μg/kg/min. At that moment, a bedside ultrasound evaluation revealed an RV diastolic dysfunction with septal flattening and "D"-shaped RV, while CVP waveform revealed a steep Y descent (Figure 3). At that moment, inhaled nitric oxide at 20 parts per million through nasal cannula and a negative hydric balance was targeted with the use of diuretics. After 24 hours, the SPAP went from 39 to 35 mm Hg and inhaled nitric oxide was weaned and replaced by 3 doses of a noninvasive combination of 60 μg of inhaled epoprostenol and 4 mg of inhaled milrinone every 6 hours using the AirLife filtered nebulizer system. Norepinephrine was weaned after the third dose. Progressive reduction in CVP Y descent (Figure 3) was observed. In addition, the portal flow pulsatility decreased from 72% to 50% 33 minutes after inhaled epoprostenol and inhaled milrinone administration (Figure 4). The patient was discharged from ICU at postoperative day 4 and uneventfully discharged home at postoperative day 6.

DISCUSSION

This is the first description of inhaled delivery of pulmonary vasodilator in non-mechanically ventilated patient to treat RV dysfunction in ICU. In both patients, reduction of filling pressure, improved hemodynamic parameters, and reduction in the severity of splanchnic venous congestion were documented. RV dysfunction increased right atrial pressure and induced venous congestion which worsens organ tissue perfusion by reducing perfusion pressure gradient between the arterial and the venous circulation. Visualization of the portal vein allows the evaluation of splanchnic venous congestion and is easily obtained in virtually every patient[3,4] through the echogenic liver parenchyma using pulsed Doppler interrogation. When combined with assessment of hemodynamic monitoring and bedside ultrasound, it can become a relevant tool to diagnose the presence of RV dysfunction. Conceptually, the hepatopetal portal flow is <30% phasic and reflects partial transmission of hepatic venous waves through hepatic sinusoids. In the setting of RV dysfunction, increase in the right heart filling pressures is transmitted, in a retrograde fashion, from right atrium to

Copyright © 2018 International Anesthesia Research Society. Unauthorized reproduction of this article is prohibited.

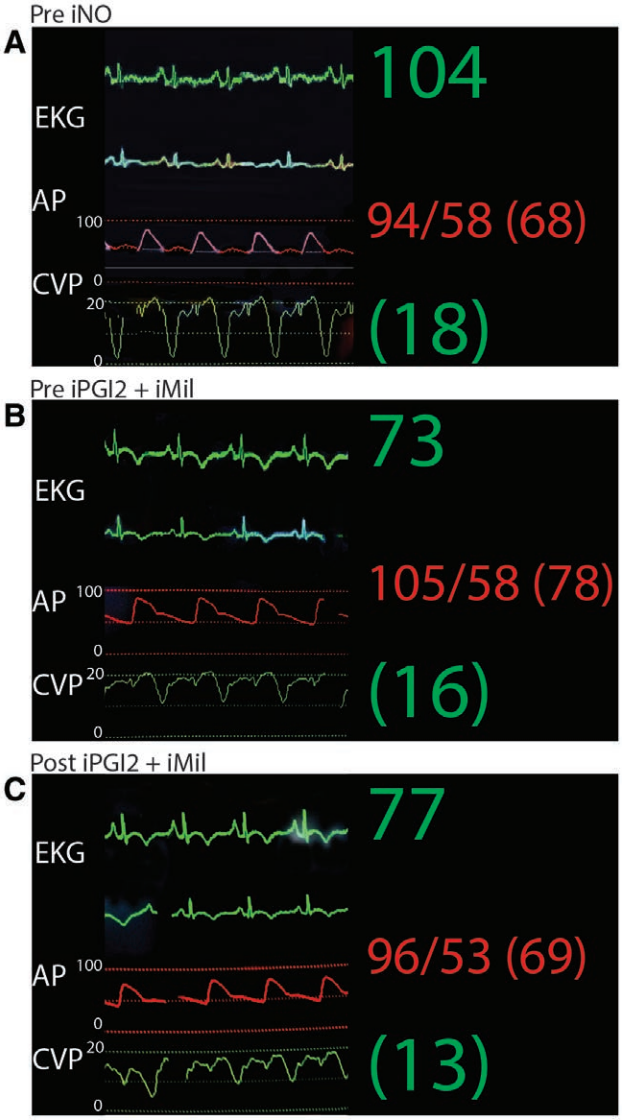

Figure 3. Patient 2 (A) CVP tracing before the initiation of iNO. Note the CVP of 18 mm Hg and the steep Y descent. B, CVP after iNO, before iPGI2 and iMil. C, CVP tracing after iPGI2 and iMil. Note the progressive decrease in CVP from 18 to 16 to 13 mm Hg and the associated decrease in the Y descent. AP indicates arterial pressure; CVP, central venous pressure; EKG, electrocardiogram; iMil, inhaled milrinone; iNO, inhaled nitric oxide; iPGI2, inhaled epoprostenol.

hepatic veins, thus reducing the liver vascular compliance and facilitating further retrograde transmission of pulsatile pressure wave to portal vein.[7] Pulsatility index is calculated as the difference between peak systolic (V1) and peak diastolic (V2) flow velocity divided by peak systolic (V1) flow velocity: (V1 − V2)/V1 (normal value <30%).[2,4] Significant portal vein pulsatility has been associated with cardiogenic portal hypertension secondary to pulmonary hypertension, RV dysfunction, and tricuspid regurgitation.[3] Portal pulsatility has been recently found to be an independent predictor of renal failure after cardiac surgery.[4]

When RV failure occurs with an acute progression of pulmonary hypertension, preload and afterload reduction are the cornerstone to prevent interventricular septum diastolic shift toward the LV and impairment of the LV diastolic filling. The pharmacological management of pulmonary hypertension is based on pulmonary vasodilators. Combination of inhaled epoprostenol and milrinone results in increase in MAP/MPAP ratio, decrease in right atrial pressure without change in systemic arterial pressure, and no increase in pulmonary shunt or the use of supplemental vasoactive agent.[1] The absorption and duration of the effect of these inhaled agents is still undetermined, but it probably lasts around 4 hours based on our local experience using inhaled milrinone.[8–11] The effect of the inhaled combination is typically seen within 30 minutes. Drug concentration during noninvasive administration has not been reported, and further studies would be required to determine the optimal interval of administration. In the 2 patients, combination therapy was used until signs of venous congestion such as portal hypertension resolved once a neutral fluid balance was achieved with diuretics.[3]

The device used for noninvasive inhalation therapy consists of a small-volume nebulizer mounted on an inspiratory limb connected with a "Y" piece to an expiratory limb equipped with an expiratory filter (Figure 1). This filtered nebulizer system can be used to deliver any kind of aerosolized respiratory medication.[12] Its configuration minimizes the environmental impact of aerosolized medication. A particular attention must be taken with epoprostenol because its preparation produces a sticky solution.[13] In order to administer the medication, the patient must collaborate.

This report is limited by the number of patients studied, and further evidence supporting the benefits of noninvasive

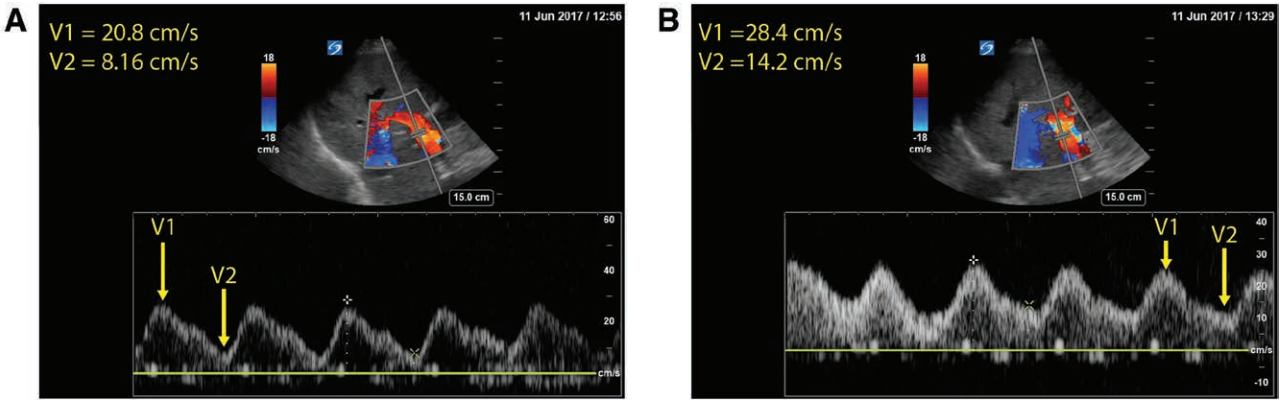

Figure 4. Patient 2 color Doppler interrogation of the portal vein before (A) and after (B) inhaled epoprostenol and inhaled milrinone. Note the change in portal pulsatility from 72% to 50% after inhaled treatment. Pulsatility index = [V1 − V2]/V1. V1 indicates peak flow velocity; V2, lowest flow velocity.

Copyright © 2018 International Anesthesia Research Society. Unauthorized reproduction of this article is prohibited.

epoprostenol and milrinone is needed. However, the hemodynamic changes observed in terms of CVP, SPAP, and MAP/MPAP are similar to those we observed using this combination in intubated patients[1] and also similar to those obtained with nitric oxide in intubated patients with RV dysfunction after myocardial infarction.[14] In addition, there is a growing body of literature on the use of noninvasive administration of inhaled nitric oxide in the neonatal literature through nasal prongs, high-flow nasal cannula, or noninvasive ventilation.[15] The combined inhaled epoprostenol and milrinone represent, in our institution, a much less expensive strategy that we use as an alternative to inhaled nitric oxide. ■

ACKNOWLEDGMENTS

The authors would like to thank Yan Cormier, chief of respiratory therapy in the intensive care unit, for his support in the development and implementation of non-invasive inhalation therapy.

DISCLOSURES

Name: Etienne J. Couture, MD.
Contribution: This author helped collect the data and write the manuscript.
Conflicts of Interest: None.
Name: Jan-Alexis Tremblay, MD.
Contribution: This author helped revise the manuscript.
Conflicts of Interest: None.
Name: Mahsa Elmi-Sarabi, MSc.
Contribution: This author helped revise the manuscript.
Conflicts of Interest: None.
Name: Yoan Lamarche, MD, MSc.
Contribution: This author helped revise the manuscript.
Conflicts of Interest: None.
Name: André Y. Denault, MD, PhD.
Contribution: This author helped instigate the report and revise the manuscript.
Conflicts of Interest: Dr Denault is on the speakers bureau for CAE Healthcare and Masimo.
This manuscript was handled by: BobbieJean Sweitzer, MD, FACP.

REFERENCES

1. Laflamme M, Perrault LP, Carrier M, Elmi-Sarabi M, Fortier A, Denault AY. Preliminary experience with combined inhaled milrinone and prostacyclin in cardiac surgical patients with pulmonary hypertension. *J Cardiothorac Vasc Anesth*. 2015;29:38–45.
2. Tremblay JA, Beaubien-Souligny W, Elmi-Sarabi M, Desjardins G, Denault AY. Point-of-care ultrasonography to assess portal vein pulsatility and the effect of inhaled milrinone and epoprostenol in severe right ventricular failure: a report of 2 cases. *A A Case Rep*. 2017;9:219–223.
3. Denault AY, Beaubien-Souligny W, Elmi-Sarabi M, et al. Clinical significance of portal hypertension diagnosed with bedside ultrasound after cardiac surgery. *Anesth Analg*. 2017;124:1109–1115.
4. Beaubien-Souligny W, Eljaiek R, Fortier A, et al. The association between pulsatile portal flow and acute kidney injury after cardiac surgery: a retrospective cohort study. *J Cardiothorac Vasc Anesth*. 2018;32:1780–1787.
5. Gebhard CE, Desjardins G, Gebhard C, Gavra P, Denault AY. Intratracheal milrinone bolus administration during acute right ventricular dysfunction after cardiopulmonary bypass. *J Cardiothorac Vasc Anesth*. 2017;31:489–496.
6. Miller RF, Godfrey-Faussett P, Semple SJ. Nebulised pentamidine as treatment for *Pneumocystis carinii* pneumonia in the acquired immunodeficiency syndrome. *Thorax*. 1989;44:565–569.
7. McNaughton DA, Abu-Yousef MM. Doppler US of the liver made simple. *Radiographics*. 2011;31:161–188.
8. Nguyen AQ, Théorêt Y, Chen C, Denault A, Varin F. High performance liquid chromatography using UV detection for the quantification of milrinone in plasma: improved sensitivity for inhalation. *J Chromatogr B Analyt Technol Biomed Life Sci*. 2009;877:657–660.
9. Gavra P, Nguyen AQ, Theoret Y, Litalien C, Denault AY, Varin F. A specific and sensitive HPLC-MS/MS micromethod for milrinone plasma levels determination after inhalation in cardiac patients. *Ther Drug Monit*. 2014;36:663–668.
10. Gavra P, Nguyen AQ, Beauregard N, Denault AY, Varin F. High-performance liquid chromatography assay using ultraviolet detection for urinary quantification of milrinone concentrations in cardiac surgery patients undergoing cardiopulmonary bypass. *Biomed Chromatogr*. 2014;28:1084–1089.
11. Denault AY, Bussières JS, Arellano R, et al. A multicentre randomized-controlled trial of inhaled milrinone in high-risk cardiac surgical patients. *Can J Anaesth*. 2016;63:1140–1153.
12. Kim CS, Garcia L, Wanner A. Actual pentamidine dose delivered by Respigard II nebulizer. *Eur Respir J*. 1995;8:2178–2181.
13. Bhatt AM, Stein EJ. Clinical complications with the delivery of inhaled epoprostenol in the operating room. *Anesthesiology*. 2017;127:383.
14. Inglessis I, Shin JT, Lepore JJ, et al. Hemodynamic effects of inhaled nitric oxide in right ventricular myocardial infarction and cardiogenic shock. *J Am Coll Cardiol*. 2004;44:793–798.
15. Ballard RA, Truog WE, Cnaan A, et al; NO CLD Study Group. Inhaled nitric oxide in preterm infants undergoing mechanical ventilation. *N Engl J Med*. 2006;355:343–353.

Copyright © 2018 International Anesthesia Research Society. Unauthorized reproduction of this article is prohibited.